

Case Report

Neurorehabilitation of a Pediatric Patient with Viral Encephalitis Caused by COVID-19: A Case Report

Ke-yi Chen, Zhuo-ming Chen^{*}, Li-min Zhong, Yi-qi Cao, Gang Wang

Department of Rehabilitation, The First Affiliated Hospital of Jinan University, Guangzhou, China

Email address:

zm120tchzm@qq.com (Zhuo-ming Chen)

^{*}Corresponding author

To cite this article:

Ke-yi Chen, Zhuo-ming Chen, Li-min Zhong, Yi-qi Cao, Gang Wang. (2023). Neurorehabilitation of a Pediatric Patient with Viral Encephalitis Caused by COVID-19: A Case Report. *American Journal of Pediatrics*, 9(4), 235-240.

<https://doi.org/10.11648/j.ajp.20230904.18>

Received: November 29, 2023; **Accepted:** December 13, 2023; **Published:** December 26, 2023

Abstract: Viral encephalitis affects brain function and can lead to various symptoms, including headaches, fever, behavioral changes, and seizures. It may even result in long-term neurological damage or other severe consequences. During the COVID-19 pandemic, it has been confirmed that SARS-CoV-2 can infect the brain and cause neurological damage, although the likelihood of this occurring is relatively rare. This case report discusses the treatment and recovery of a pediatric patient with viral encephalitis caused by COVID-19. A 3-year-old boy developed severe symptoms, including high fever, altered consciousness, and seizures. The child was diagnosed with viral encephalitis after testing positive for the coronavirus in a reverse transcription polymerase chain reaction (RT-PCR) test. He underwent brain MRI, Magnetic resonance spectroscopy (MRS), and electroencephalography (EEG) examinations, revealing certain neurological damage. During the rehabilitation therapy that included motor training, speech therapy, and sensory integration training, we found that this damage manifested as significant neurological impairments, including difficulties with sensory integration, speech, and cognitive abilities. Following the completion of these rehabilitation exercises, the child's neurological functions and social abilities improved. Therefore, in children post-COVID-19 infection, vigilance for potential impacts on the nervous system is necessary, and early intervention with rehabilitation treatment is required.

Keywords: COVID-19, Viral Encephalitis, Neurological Complications, Pediatric Neurorehabilitation

1. Introduction

Coronavirus disease 2019 (COVID-19) is a human-to-human transmitted disease caused by SARS-CoV-2 infection. The first case was confirmed in late 2019 in Wuhan, Hubei Province, China [1]. Multiple studies have found that SARS-CoV-2 can invade nerve cells and cause neurologic damage. The central nervous system symptoms include dizziness, headache, consciousness disorders, acute cerebrovascular diseases, ataxia, and seizures. Peripheral nervous system symptoms include taste disorders, olfactory disorders, visual impairments, and neuropathic pain [2, 3]. Viral encephalitis refers to a series of neurological damage caused by viral infection, either directly through the central nervous system infection or indirectly through immune

reactions that lead to brain tissue damage [4]. With the relaxation of epidemic control measures against the Omicron variant in mainland China towards the end of 2022, a surge in COVID-19 cases was observed. This led to first-time infections in many, including infants and the elderly, with some showing severe clinical manifestations [5, 6]. This case report introduces the clinical symptoms and prognosis of a male infant diagnosed with COVID-19, highlighting the importance of neurologic damage and subsequent rehabilitation therapy after SARS-CoV-2 infection.

2. Case Report

2.1. Clinical Information

A 3-year-old male child developed a fever in the early

morning of December 20, 2022, with a peak temperature of 38.9°C. He occasionally coughed, without experiencing chills or convulsions. A SARS-CoV-2 antigen rapid test at home yielded a positive result, and the family administered oral antipyretic medication, reducing the temperature to 38°C. However, the patient continued to have recurrent high fevers, reaching a maximum temperature of 42°C. On the same day, he sought medical attention due to sudden onset of altered consciousness accompanied by seizures. He had a Glasgow Coma Scale score of 4 (E2V1M1), was lethargic, and had bilaterally sluggish pupil responses and increased muscle tone. After rescue measures, including sedation, the seizure symptoms improved. His COVID-19 nucleic acid test was positive, and he showed elevated neutrophil percentages, high-sensitivity C-reactive protein, and interleukin-6 levels, with D-dimer levels also raised. Head CT scans showed no significant abnormalities. Subsequently, the child experienced another episode of loss of consciousness, and despite sedation, remained in a state of unconsciousness. He was then

transferred to the Pediatric Intensive Care Unit (PICU) for further treatment. During the PICU stay, the child received assisted ventilation with endotracheal intubation, anti-infection treatment, antiepileptic therapy, plasma exchange, and comprehensive treatment with steroids. After nearly two weeks of treatment, the child successfully weaned off mechanical ventilation, regained consciousness, showed minimal responsiveness to his name being called, poor response to commands, exhibited smiles and limb movements, but lacked spontaneous speech. An MRI scan revealed findings reversible cerebral vasoconstriction syndrome (RCVS), posterior reversible encephalopathy syndrome (PRES), encephalitis. Following stabilization, he was transferred to a regular ward for rehabilitation. After a month of rehabilitation, he discontinued systematic training. In May 2023, he developed symptomatic epilepsy, with impairments in limb movement, speech, and cognitive abilities. Treatment with levetiracetam and zonisamide for epilepsy was started, along with resumed systematic rehabilitation training.

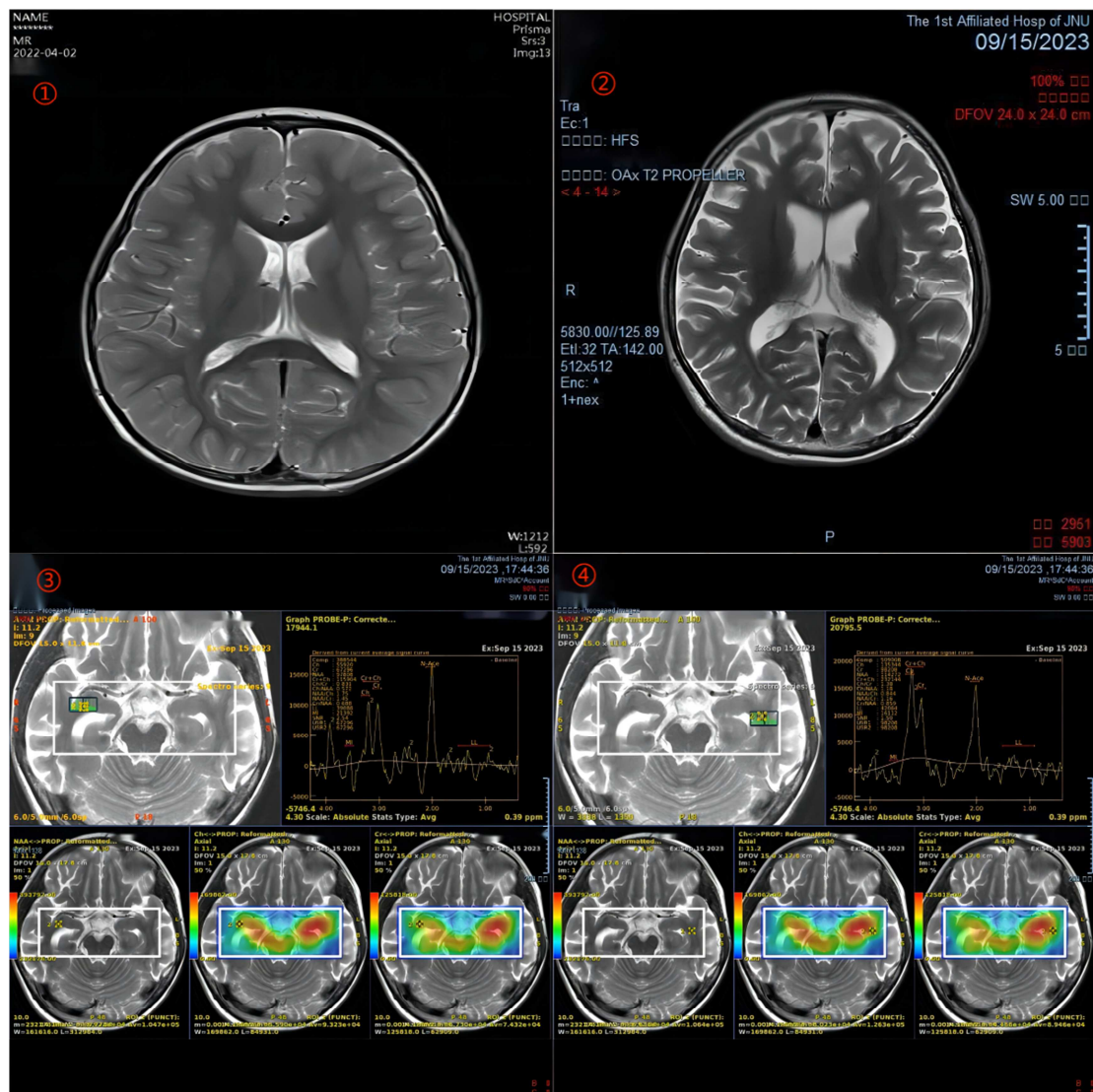


Figure 1. ① Before the onset of the illness, the child's head MRI plain scan did not reveal any abnormalities. ② Post-COVID-19 Infection, the head MRI plain scan of the child showed abnormal signals in the brain, suggesting encephalitis, and bilateral parieto-occipital brain atrophy. ③&④ Magnetic resonance spectroscopy (MRS) was performed in the bilateral frontal lobes, temporal lobes, and hippocampal regions.

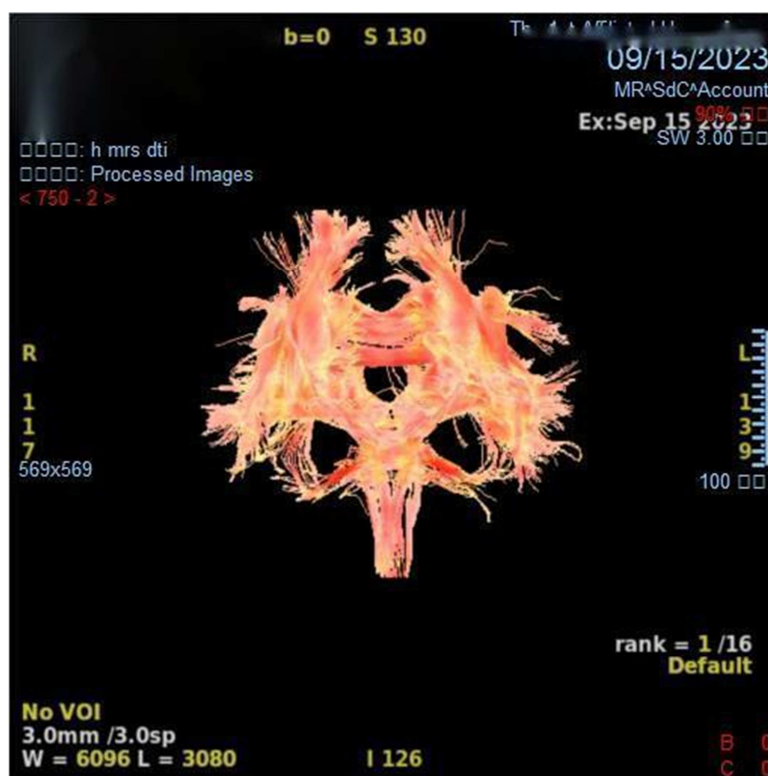


Figure 2. DTI reveals that although the fiber pathways in both cerebral hemispheres follow a normal and largely symmetrical course, there is a noticeable reduction in fiber density on the right side compared to the left side according to imaging.

2.2. Rehabilitation Assessment

During the rehabilitation period, a comprehensive assessment was conducted for the child using the Pediatric Sensory Integrative Function Scale (SIFS). The assessment outlined the child's sensory integration development and the severity of sensory integration dysfunction, serving as a tool for comparing the effectiveness of sensory integration rehabilitation before and after treatment [7]. The initial assessment was carried out upon completion of the first systematic rehabilitation training before discharge. At that time, the child's gross motor skills were close to the level of same-aged children. He displayed emotional stability and did

not exhibit excessive defensive reactions to the external environment. His proprioceptive and balance coordination abilities were also comparable to those of typically developing peers. Following the onset of symptomatic epilepsy, the child experienced a comprehensive regression in sensory integration capabilities. Concerns were raised about potential tendencies toward autism spectrum disorders based on the results of the Autism Behavior Checklist (ABC) [8]. After three months of rehabilitation training, a reassessment revealed some improvement in the child's reduced defensive reactions to the external environment. However, limb movement and proprioceptive capabilities remained suboptimal compared to the previous assessment.

Table 1. Assessment Situations of the Sensory Integrative Function Scale.

Date	Gross Motor Skills and Balance Sense	Tactile Defensiveness	Proprioception
January 29, 2023	Mild Dysfunction	Normal	Normal
June 27, 2023	Severe Dysfunction	Severe Dysfunction	Severe Dysfunction
September 18, 2023	Severe Dysfunction	Normal	Severe Dysfunction

Table 2. Assessment Situations of the Autism Behavior Checklist.

Date	Total Score	Sensory	Relating	Body and Object Use	Language	Social and Self-Help
January 29, 2023	59	12	11	7	17	12
June 27, 2023	77	9	14	16	18	20
September 18, 2023	74	16	8	15	21	14

2.3. Rehabilitation Treatment

The content and approach of rehabilitation training were tailored to the needs and condition of the child. Our

rehabilitation treatment included the following aspects:

2.3.1. Motor Training and Occupational Training

The child exhibited motor difficulties primarily in the areas of coordination, balance, and flexibility. The content of motor

training encompassed building muscle strength, improving balance, and engaging in a rehabilitation model that coordinated active and passive movements. Due to limitations in the child's daily life activities, occupational training was also incorporated. To enhance the child's interest in motor rehabilitation, task-oriented occupational therapy with higher levels of fun was implemented. This involved activities such as using sandpaper boards, building blocks, dressing and undressing, playing marbles, and other interesting tasks aimed at improving the patient's motor function and coordination. The goal was to restore the child's ability to perform daily life activities. Motor and occupational training were typically conducted once a day, with the content of each session varied as much as possible, and each session lasting approximately 30 minutes.

2.3.2. Articulation Training and Speech Training

The current presentation of the child indicates poor articulation clarity, lower abilities in forming sentences, and reduced semantic expression and comprehension compared to same-aged typically developing children. Therefore, our focus is on correcting the child's articulation abilities and improving language comprehension and expression through listening, speaking, reading, and writing. In terms of listening training, we use engaging animations, music, and other stimuli to expose the child to different syllables, word combinations, or sentences, aiding the child in distinguishing correct pronunciations. For speaking training, emphasis is placed on training and correcting the oral muscle movements involved in pronunciation to enhance accuracy. Specific exercises include activities such as blowing up balloons, whistling, and suction, targeting muscle strength and coordination in the oral cavity. Jaw movement, lip-tongue movement, and soft palate movement exercises are integrated to train the child's ability to pronounce single syllables. Concurrently, alternating movements involving the jaw, lips, and tongue are introduced to provide variety and improve the child's accuracy and fluency in pronouncing short and long sentences. For reading and writing, considering the child's current age and cultural level, the recognition of Chinese characters is limited. Therefore, while providing education similar to that of same-aged children, the approach focuses more on a guided and sensory-combined educational model, emphasizing imitative reading and drawing training. Articulation and speech training are adjusted based on the child's patience and interest, conducted 1-2 times per day, with each session lasting approximately 30 minutes.

2.3.3. Sensory Integration Training

During rehabilitation, we observed that the child exhibits heightened defensiveness to tactile stimuli. To address this, we implemented activities such as desensitization with a brush and facial sticking games. These activities aim to enhance the child's skin contact stimuli, reduce hypersensitive or delayed tactile responses, and improve the child's tactile recognition and hand-eye coordination. Considering the child's abnormalities in vestibular and proprioceptive senses, we inclined towards activities like chair spinning and

mini-carousel games to stimulate the child's vestibular system. These games are designed to cultivate the child's balance coordination and limb movement abilities, with the hope of enhancing the child's concentration and emotional control. This process also requires the involvement and cooperation of parents, fostering interaction between the child and parents to increase the training's enjoyment and family integration. It's important to note that the duration of sensory integration training should be personalized based on the severity of the child's challenges and emotional state. Typically, sessions last for 30 minutes to 1 hour each day.

3. Discussion

3.1. Neurological Changes Worthy of Attention Following Post-COVID-19 Infection

Complications of the nervous system after novel coronavirus infection include damage to both the central and peripheral nervous systems, manifested primarily as headaches, altered consciousness, seizures, cerebrovascular diseases, taste or smell disorders, visual impairment, and more [2, 3, 9]. The mechanisms behind neurological damage after novel coronavirus infection are not yet fully understood and may be related to factors such as direct viral invasion of nerve cells, systemic inflammatory response caused by the virus, blood clotting abnormalities, hypoxemia, and drug side effects [10]. In the presented case, the child exhibited a rapid increase in infection markers and a hypercoagulable state after novel coronavirus infection. This was accompanied by symptoms such as high fever, altered consciousness, seizures, encephalitis, and damage to the central nervous system, as well as impairments in speech and cognitive abilities and sensory integration. These impairments may be associated with direct damage to brain tissue by the virus or immune reactions leading to brain edema, cerebral vasoconstriction, and cerebral thrombosis. In light of the child's cranial MRI scan results in this case, RCVS, PRES, encephalitis, and bilateral brain atrophy were considered. Further confirmation of neurological abnormalities was provided by the results of EEG and MRS, indicating a connection between these lesions and neurological damage following novel coronavirus infection [11, 12].

3.2. Early Neurorehabilitation for Viral Encephalitis Following Post-COVID-19 Infection

The existing literature indicates that the incidence of viral encephalitis following novel coronavirus infection is relatively low. However, the prognosis of such cases is often poor, potentially resulting in permanent neurological damage or even death [13]. Therefore, for patients with viral encephalitis following novel coronavirus infection, in addition to providing symptomatic treatment such as antiviral, antiepileptic, anti-inflammatory, and intracranial pressure-lowering medications, early initiation of neurorehabilitation vital for mitigating neurological damage and enhancing patient recovery and quality of life. This aims to alleviate neurological damage, promote neurological recovery, and improve the patient's quality of life and prognosis. The timing of

neurorehabilitation should be determined based on the patient's condition and tolerance, generally commencing once the patient's condition has stabilized [14]. In the case of the presented child, simple bedside rehabilitation training began after successfully discontinuing respiratory support. The content and methods of neurorehabilitation should be tailored to the specific needs and conditions of the patient. In this case, the child showed improvement in neurological function after undergoing a combination of movement training, task-oriented training, speech therapy, articulation training, and sensory integration training.

3.3. The Role of Rehabilitation Therapy in Neurological Damage Caused by COVID-19 Infection

Rehabilitation therapy is a comprehensive treatment method for functional impairments following neurological damage. Its goal is to stimulate and train the patient's residual functions, promote the reshaping and recovery of the nervous system, and enhance the patient's self-care and social adaptation abilities [15]. Rehabilitation therapy has played a crucial role in addressing movement and speech disorders that may arise after COVID-19 infection-induced viral encephalitis. Movement disorders, such as muscle weakness, abnormal muscle tone, coordination difficulties, and balance impairments, can significantly impact a patient's daily life. Rehabilitation therapy, through movement training, can improve muscle strength, muscle tone, coordination, and balance, thereby enhancing the patient's daily life skills. Speech disorders, including aphasia, articulation issues, and fluency problems, can affect a child's

communication and social participation. Rehabilitation therapy, through speech and articulation training, can improve language comprehension and expression, restoring language function [16]. Sensory integration training is a personalized rehabilitation training mode designed to stimulate sensory activities and promote the formation of new neural connections in the brain, improving neurological function. It is mainly achieved through games or activities to alleviate the severity of sensory integration dysfunction [17]. Therefore, including rehabilitation therapy, including sensory integration training, is essential for addressing neurological damage caused by novel coronavirus infection, as it can improve the patient's neurological function, thereby enhancing their quality of life and confidence.

3.4. Limitations

This case study illustrates the potential neurological damage and the importance of rehabilitation therapy after infection with the novel coronavirus, providing valuable information for clinical practice and scientific research. However, the limitations of this case are noteworthy. It is a single case and cannot represent all situations of neurological damage after infection with the novel coronavirus. Furthermore, it cannot determine the exact mechanisms of neurological damage and the optimal rehabilitation therapy for such cases. More cases and research are needed to validate and refine these findings.

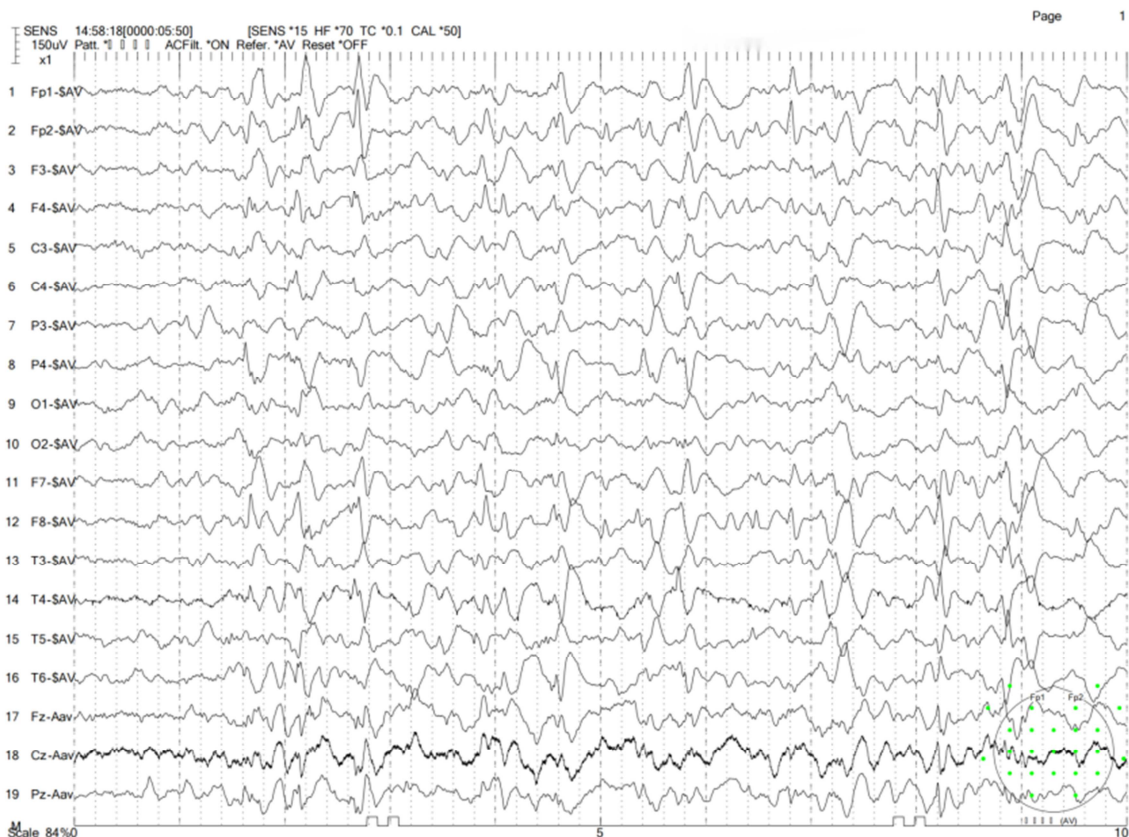

Figure 3. EEG shows bilateral asymmetry in brain waves. Consideration of abnormal EEG patterns for the age group and possible medication-induced sleep EEG abnormalities.

4. Conclusions

Infection with the COVID-19 may lead to central nervous system damage, including encephalitis and neuronal injury, subsequently affecting sensory integration and language cognitive abilities. For patients exhibiting neurological symptoms after a COVID-19 Infection, timely neurological examination and assessment should be conducted to clarify the diagnosis and condition. Comprehensive treatment and rehabilitation training should be provided to alleviate neurological damage and functional impairments, thereby improving the patient's quality of life and prognosis. Additionally, rehabilitation therapy should be carried out regularly and for an extended duration, without interruption or abandonment, with the goal of achieving the best possible outcome.

Funding

This work was supported by the National Key R&D Program of China. (Grant Number: LHGJ20191241) and the Key Science & Technology Brainstorm Project of Guangzhou (202103000027).

Conflicts of Interest

All the authors declare they have no conflict of interest.

References

- [1] Wang D, Hu B, Hu C, et al. Clinical Characteristics of 138 Hospitalized Patients With 2019 Novel Coronavirus–Infected Pneumonia in Wuhan, China. *JAMA*. 2020 Mar 17; 323(11): 1061-1069. doi: 10.1001/jama.2020.1585.
- [2] Huang C, Wang Y, Li X, Ren L, et al. Clinical features of patients infected with 2019 novel coronavirus in Wuhan, China. *Lancet*. 2020 Feb 15; 395(10223): 497-506. doi: 10.1016/S0140-6736(20)30183-5.
- [3] Helms J, Kremer S, Merdji H, et al. Neurologic Features in Severe SARS-CoV-2 Infection. *N Engl J Med*. 2020 Jun 4; 382(23): 2268-2270. doi: 10.1056/NEJMc2008597.
- [4] A. Venkatesan, Tunkel AR, Bloch KC, et al. Case definitions, diagnostic algorithms, and priorities in encephalitis: consensus statement of the international encephalitis consortium. *Clin Infect Dis*. 2013 Oct; 57(8): 1114-28. doi: 10.1093/cid/cit458.
- [5] Suzuki R, Yamasoba D, Kimura I, Wang L, et al. Attenuated fusogenicity and pathogenicity of SARS-CoV-2 Omicron variant. *Nature*. 2022 Mar; 603(7902): 700-705. doi: 10.1038/s41586-022-04462-1.
- [6] He Y, Zhang F, Liu Y, et al. Clinical Characteristics of Mild Patients with Breakthrough Infection of Omicron Variant in China after Relaxing the Dynamic Zero COVID-19 Policy. *Vaccines*. 2023 May 10; 11(5): 968. doi: 10.3390/vaccines11050968.
- [7] Geng H. Study on the Effect of SIT Therapy Based on Ayres Sensory Integration Theory on Children Aged 3-6 with Autism Spectrum Disorder. *Tianjin University of Sport*, 2023. doi: 10.27364/d.cnki.gttyy.2023.000288.
- [8] Kat S, Xu L, Guo Y, et al. Reliability and Validity of the Simplified Chinese Version of the Aberrant Behavior Checklist in Chinese Autism Population. *Front Psychiatry*. 2020 Oct 14; 11: 545445. doi: 10.3389/fpsy.2020.545445.
- [9] Panda PK, Sharawat IK, Panda P, et al. Neurological Complications of SARS-CoV-2 Infection in Children: A Systematic Review and Meta-Analysis. *J Trop Pediatr*. 2021 Jul 2; 67(3): fmaa070. doi: 10.1093/tropej/fmaa070.
- [10] Johansson A, Mohamed MS, Moulin TC, Schiöth HB. Neurological manifestations of COVID-19: A comprehensive literature review and discussion of mechanisms. *J Neuroimmunol*. 2021 Sep 15; 358: 577658. doi: 10.1016/j.jneuroim.2021.577658.
- [11] Cecchetti G, Agosta F, Canu E, et al. Cognitive, EEG, and MRI features of COVID-19 survivors: a 10-month study. *J Neurol*. 2022 Jul; 269(7): 3400-3412. doi: 10.1007/s00415-022-11047-5.
- [12] Rapalino O, Weerasekera A, Moum SJ, et al. Brain MR Spectroscopic Findings in 3 Consecutive Patients with COVID-19: Preliminary Observations. *AJNR Am J Neuroradiol*. 2021 Jan; 42(1): 37-41. doi: 10.3174/ajnr.A6877.
- [13] Islam MA, Cavestro C, Alam SS, et al. Encephalitis in Patients with COVID-19: A Systematic Evidence-Based Analysis. *Cells*. 2022 Aug 18; 11(16): 2575. doi: 10.3390/cells11162575.
- [14] Christie S, Chan V, Mollayeva T, Colantonio A. Systematic review of rehabilitation intervention outcomes of adult and paediatric patients with infectious encephalitis. *BMJ Open*. 2018 May 14; 8(5): e015928. doi: 10.1136/bmjopen-2017-015928.
- [15] Mary P. Neuro-Rehabilitation Program Treatment: Principles and Process. In *Successful Private Practice in Neuropsychology and Neuro-Rehabilitation: A Scientist-Practitioner Model*. Cambridge, Massachusetts: Academic Press; 2015, pp. 129-165.
- [16] Chen Z. *Language Rehabilitation for Special Needs Children*. Beijing, China: People's Medical Publishing House; 2015, pp. 148-152.
- [17] Chen Z. *Mental and Cognitive Rehabilitation*. Beijing, China: People's Medical Publishing House; 2017, pp. 231-252.